

IOF SKELETAL RARE DISEASES ACADEMY

(XLH) HDGXORW

PHOCEK PENCXG [CNIØKVOØGFKCIPUVKEQ

NTC SW KVKU O QKRØC U HC VØ KEØK C FØ NETØ Ø Ø C ::*GU
W PCIRUPDKHUHGLWØØUØDGHWUDVWRUØSRUSØJGLGDGHIRVI
UHØØRGTØPVTGNC U HØØ C U JGTGFKVC TKC U GU NC O U EQ PØ
W PC RTGXC NGPEKC GU VKO C FØFEBLHØRV

DIAGNÓSTICO

El diagnóstico, cuando lo hay, se basa en una historia clínica coherente, una exploración física, pruebas radiológicas de raquitismo, exámenes bioquímicos y, de existir, una historia familiar que sugiera la aparición multigeneracional o esporádica de XLH. El diagnóstico diferencial incluye el raquitismo nutricional, la displasia metafisaria y otras formas de trastornos renales por pérdida de fosfato.

Manifestaciones clínicas

Craneal

- Protuberancia frontal
- Craniosinostosis que puede estar asociada a la malformación de Chiari
- Pérdida de audición

Dental

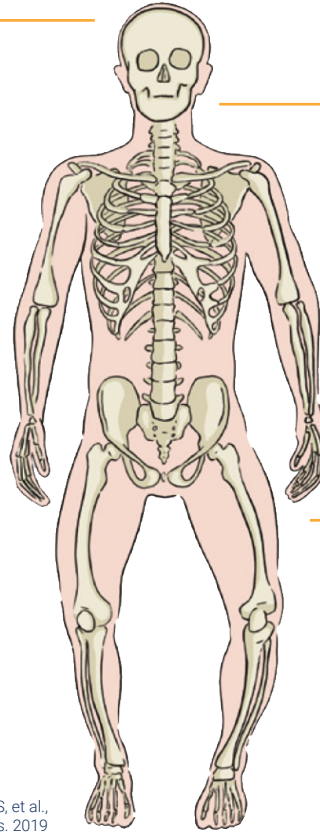
- Abscesos dentales
- Defectos del esmalte
- Cámaras pulpaes agrandadas
- Taurodontismo

Esqueleto y articulaciones

- Short stature
- Lower limb deformities
- Osteomalacia (including pseudo-fractures, early-onset osteoarthritis, enthesopathy leading to joint restriction)
- Waddling gait
- Bone and joint pain
- Muscle pain and weakness
- Spinal stenosis

Otras

- Fatigue
- Mobility restriction
- Mental health issues
- Diminished quality of life



Beck-Nielsen SS, et al.,
Orphanet J Rare Dis. 2019

Laboratory Analysis

Serum values	Urine values
Low phosphate* Elevated bone alkaline phosphatase Normal calcium** Normal PTH** Normal 25(OH) vitamin D Low or inappropriately normal 1,25(OH) ₂ D ₃ Elevated intact FGF23*	Elevated or inappropriately normal phosphate*** Reduced TmP/GFR****

TmP/GFR: tubular maximal reabsorption of phosphate adjusted for glomerular filtration rate

*Fasting before sampling is required to give an accurate result

**Secondary hyperparathyroidism is common in patients with XLH, which can impact serum PTH and calcium concentration accordingly

*** Second morning void urine or urine collected over 24 hours

**** TmP/GFR is calculated from fasting paired plasma and second morning void urine samples obtained 2 hours after the first void urine for phosphate and creatinine

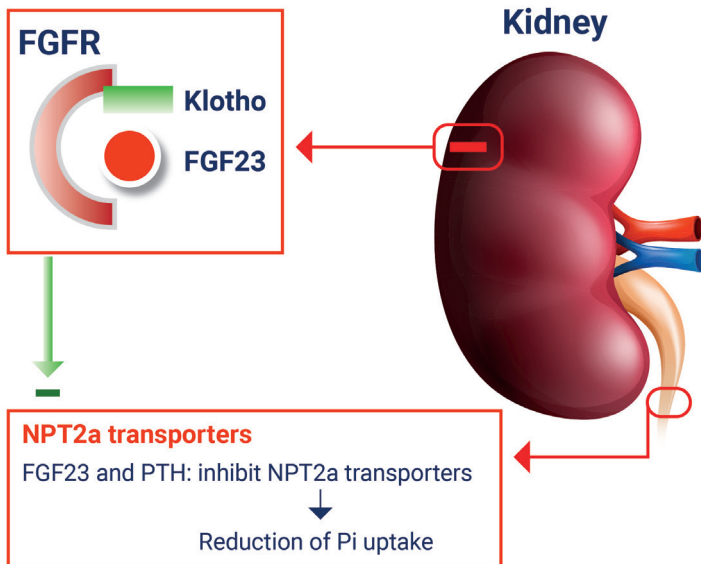
Radiographic Evaluation

- ▶ Pseudofractures
- ▶ Enthesopathy/mineralization of tendons and ligaments around the Achilles, knees, hips and spine
- ▶ Early-onset osteoarthritis

GENETICS

XLH is caused by a variety of inactivating mutations in the *PHEX* (phosphate regulating endopeptidase homolog X-linked) gene. This gene is located on chromosome Xp22.1, and is expressed in osteocytes and odontoblasts. The *PHEX* gene codes for a transmembrane endopeptidase protein belonging to the type II integral membrane zinc-dependent endopeptidase family. Alternative splicing results in multiple transcript variants. More than 300 kinds of mutations have been reported. Other genetic and environmental factors may influence the clinical manifestations of this disease. Sporadic cases occur in about one third of individuals with XLH.

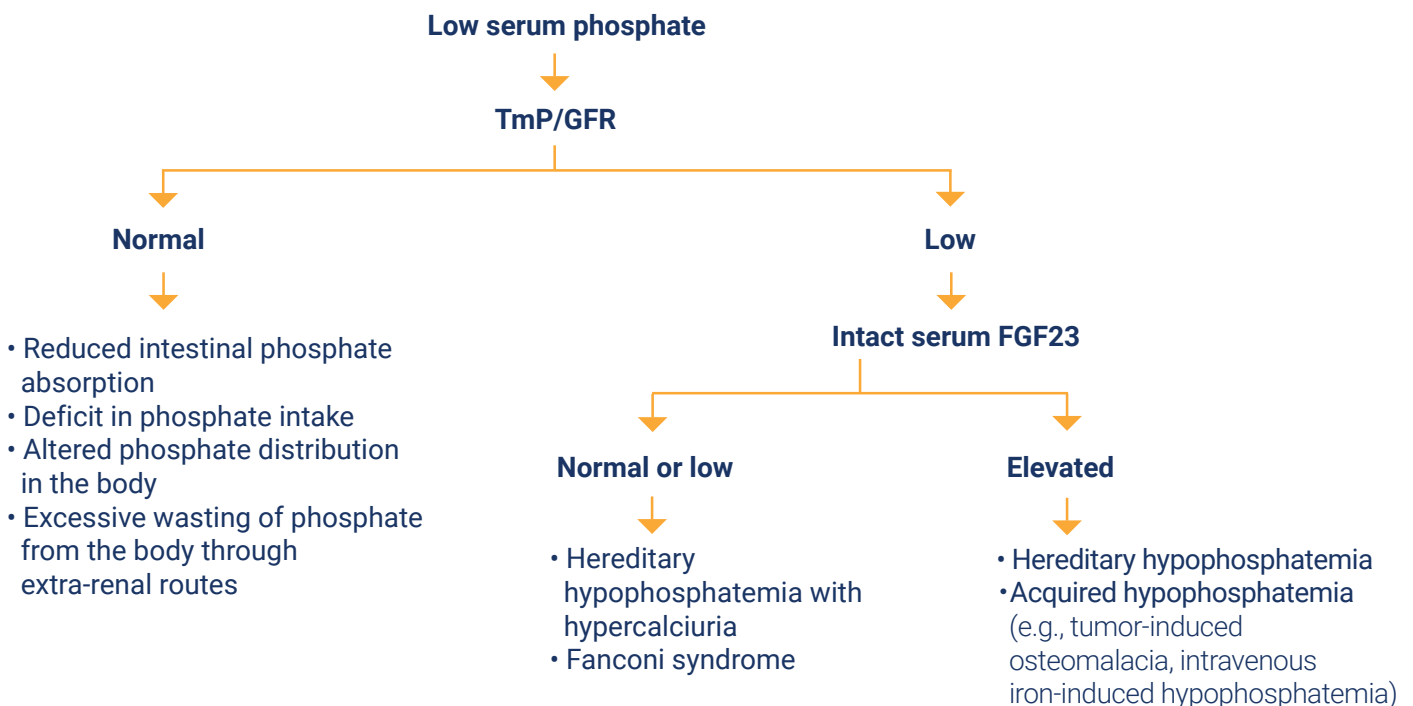
PATHOPHYSIOLOGY



Fibroblast growth factor 23 (FGF23), a hormone primarily secreted by osteocytes and osteoblasts, regulates phosphate metabolism together with parathyroid hormone (PTH) and $1,25(\text{OH})_2\text{D}_3$. Mutations of the *PHEX* gene, which is highly expressed in these bone cells and teeth, lead to increased release of FGF23 into the serum and increased level of the FGF23-mediated signalling pathway. These link to impaired renal phosphate resorption by reducing the expression of the renal Na-Pi co-transporters (NPT2a, NPT2c).

In addition, FGF23 decreases the synthesis of $1,25(\text{OH})_2\text{D}_3$ in the renal proximal tubules by downregulating CYP27B1 (encoding 1α -hydroxylase enzyme), leading to reduced conversion of $25(\text{OH})$ vitamin D to $1,25(\text{OH})_2\text{D}_3$. FGF23 also upregulates CYP24A1 (encoding 24-hydroxylase enzyme), which converts $25(\text{OH})$ vitamin D and $1,25(\text{OH})_2\text{D}_3$ into inactive metabolites. Accordingly, decreased $1,25(\text{OH})_2\text{D}_3$ results in decreasing phosphate absorption from the intestines.

ALGORITHM FOR THE EVALUATION OF A PATIENT WITH LOW SERUM PHOSPHATE LEVELS



MANAGEMENT OF XLH

▶ Patient education

- What is XLH?
- What are the typical signs and symptoms?
- What are the next steps for diagnosis and treatment initiation?
- How to manage complications and live with XLH
- How to receive support for patients and their families

▶ Nonpharmacological management

- Lifestyle
 - Physical activity
 - Prevention and treatment of obesity
 - Control of risk factors (smoking, alcohol) and calcium intake
- Physiotherapy to manage musculoskeletal complications
- Management of dental health
- Management of hearing impairment

▶ Pharmacological intervention

- Bone and joint pain control after identification of the cause of the pain
- Conventional treatment

Oral phosphate supplementation and active vitamin D analogs

These medications should be appropriately prescribed and monitored with regular follow-up, blood and urine examinations, including serum PTH and urinary calcium.

In adults, these treatments are generally prescribed in the following cases:

- Presence of clinical symptoms, especially osteomalacia with recurrent pseudofractures
- Upcoming orthopaedic surgery
- Biochemical evidence of osteomalacia with elevated ALP

These medications should be discontinued one week prior to initiation of a monoclonal antibody for FGF23 (burosumab).

- Human monoclonal antibody for FGF23 (burosumab)

Burosumab (CRYSVITA®) is a recombinant human monoclonal IgG1 antibody against FGF23. Initiation of burosumab is recommended in adults with XLH in the following cases:

- Persistent bone and/or joint pain due to XLH and/or osteomalacia that limits daily activities
- Insufficient response or refractory to conventional therapy
- Complications related to conventional therapy

The recommended starting dose of burosumab in adults is 1.0 mg/kg of body weight (maximum dose of 90 mg) every 4 weeks. Fasting serum phosphorus level should be monitored 2 weeks post-dose for the first 3 months of treatment.

▶ Surgical intervention

- Orthopaedic surgery
 - especially for:
 - Marked leg bowing with immediate functional consequences
 - Joint complications
- Neurosurgical posterior decompression
 - Spinal cord compression due to spinal stenosis

References:

- 1) Trombetti A, et al. Interdisciplinary management of FGF23-related phosphate wasting syndromes: a Consensus Statement on the evaluation, diagnosis and care of patients with X-linked hypophosphataemia. *Nat Rev Endocrinol.* 2022
- 2) Beck-Nielsen SS, et al. FGF23 and its role in X-linked hypophosphatemia-related morbidity. *Orphanet J Rare Dis.* 2019
- 3) Haffner D, et al. Clinical practice recommendations for the diagnosis and management of X-linked hypophosphataemia. *Nat Rev Nephrol.* 2019
- 4) Kinoshita Y, et al. X-Linked Hypophosphatemia and FGF23-Related Hypophosphatemic Diseases: Prospect for New Treatment. *Endocr Rev.* 2018
- 5) Marcucci G, et al. Phosphate wasting disorders in adults. *Osteoporos Int.* 2018
- 6) Masi L, et al. Taxonomy of rare genetic metabolic bone disorders. *Osteoporos Int.* 2015